

# Wolff-Parkinson-White (WPW) Syndrome

## Definition

Pre-excitation disorder of the cardiac conduction system, predisposing one to re-entrant tachyarrhythmias.

## History and Physical Exam

Often asymptomatic, but may have history suggestive of tachyarrhythmias: palpitations, chest pain, SOB, dizziness and/or syncope.

## Key 12-Lead Features

Short PR interval and characteristic Delta wave.

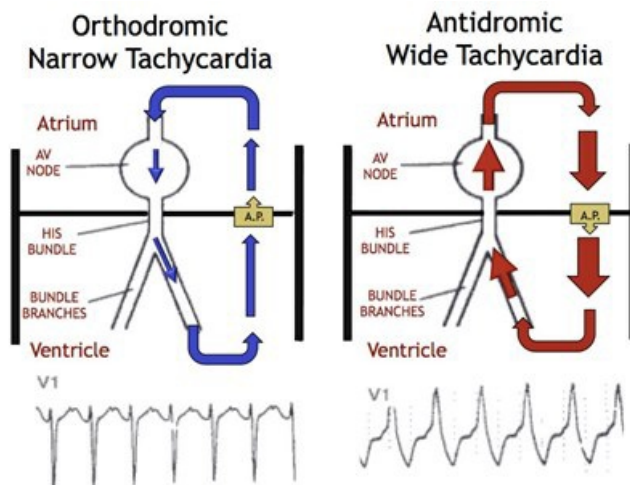
During captured AVRT episodes: orthodromic WPW is a Narrow Complex Tachycardia and looks like an SVT; antidromic WPW is a Wide Complex Tachycardia and looks like VT.

## Key Treatment Points

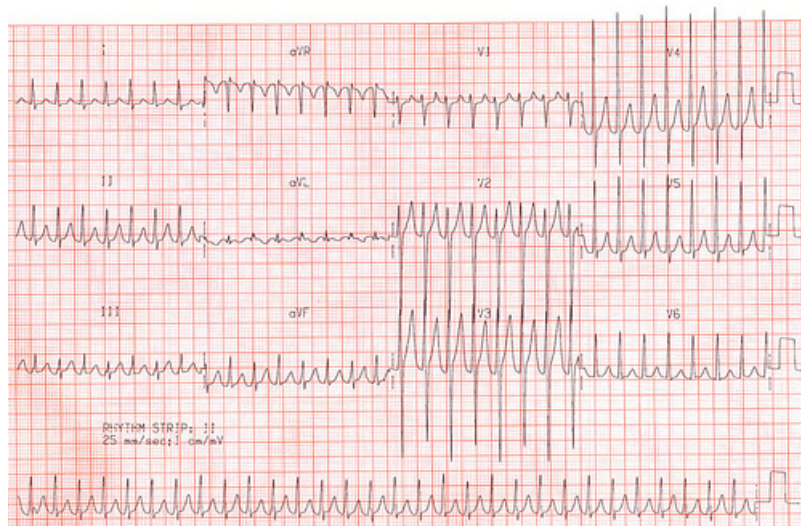
No adenosine with concurrent Atrial-Fibrillation (or any irregular rhythm)

If unstable, proceed directly to electrical cardioversion

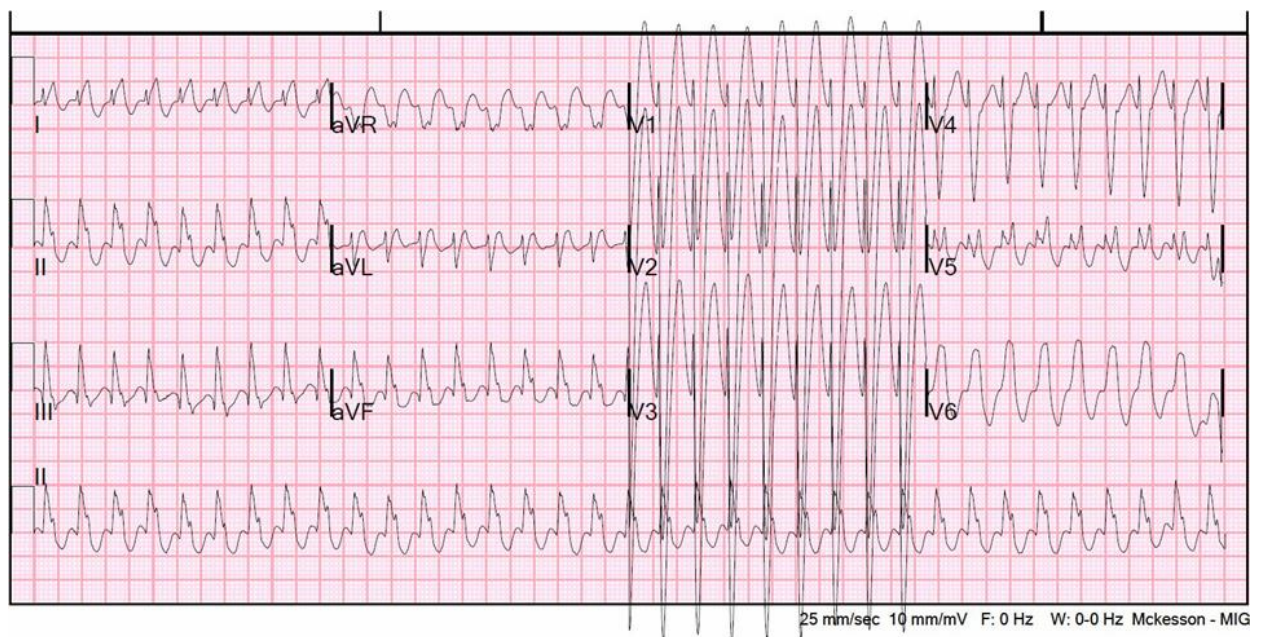
## 12 Lead ECG Samples



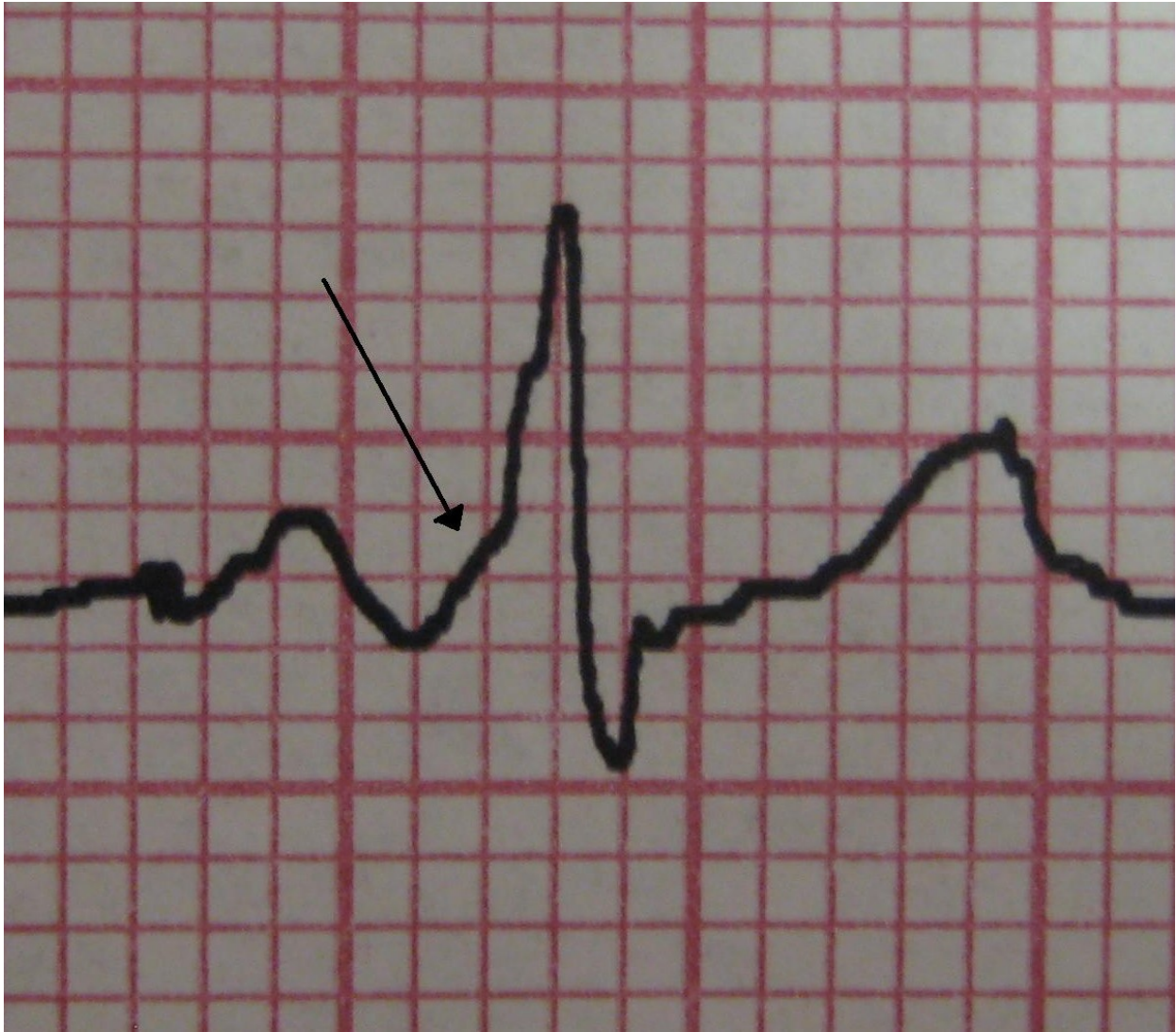Orthodromic WPW tachycardia episode



Antidromic WPW tachycardia episode



Delta Wave



[Further Reading](#)

## Reference

1. Stroobandt RX, et al. ECG from Basics to Essentials: Step by Step. 2015. [\[Link\]](#)

