

Long QT Syndrome

Definition

Prolonged QT interval; a propensity to ventricular tachy-arrhythmias, syncope, cardiac arrest, or sudden death.

History/Physical Exam

May be congenital or due to hypomagnesemia/kalemia (diuretics, malnourished), hypothermia, Rx (amiodarone, cipralex, methadone, etc). Family history of unexplained sudden death.

Presents with syncope from adrenergic stimuli - such as exercise, emotion, loud noise, swimming.

Key 12-Lead Features

QTc > 0.46 (women)

QTc > 0.45 (men)

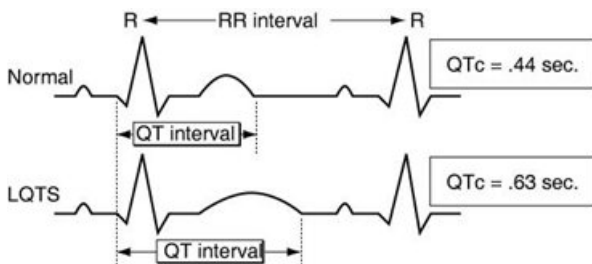
T-wave alternans

Key Treatment Points

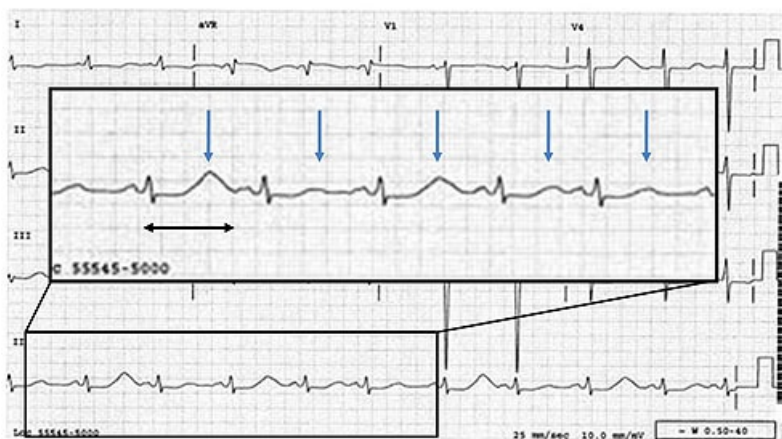Watch for Torsade de Pointes

If patient arrests, Magnesium Sulfate is indicated

12 Lead ECG Samples



Notice the T-Wave alternans below



[Further Reading](#)

References

El-Sherif, N., Turitto, G., & Boutjdir, M. (2017). Congenital Long QT syndrome and torsade de pointes. *Annals of Noninvasive Electrocardiology*. doi:10.1111/anec.12481.

