

DeWinter's T-Waves

Definition

Early warning of an evolving STEMI.

History/Physical Exam

History and findings suggestive of acute coronary syndrome.

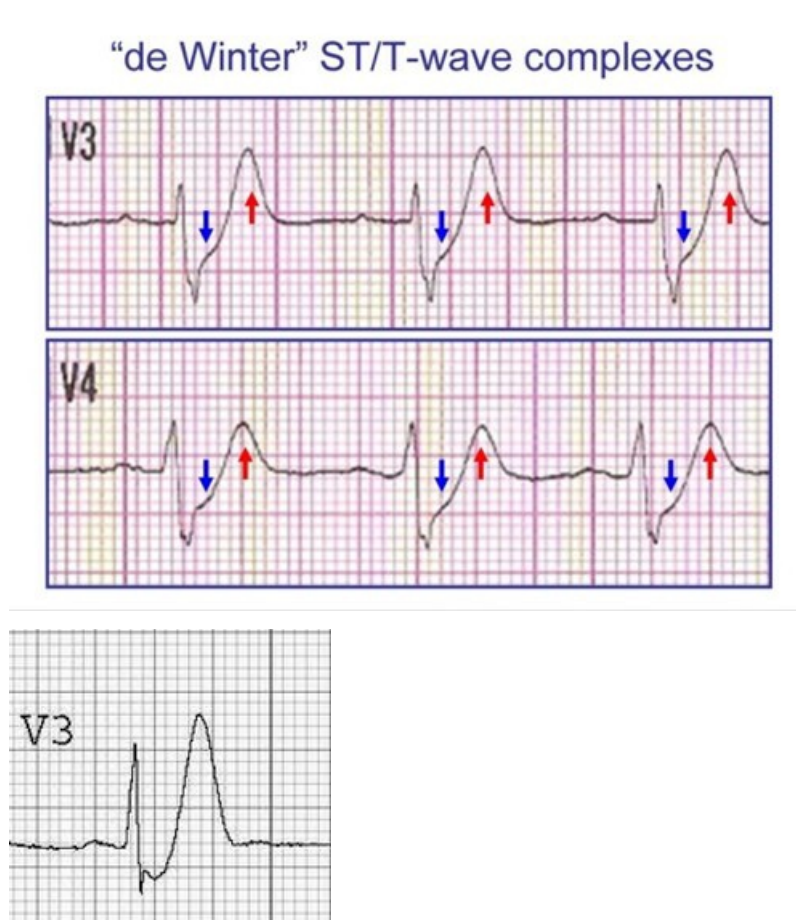
Key 12-Lead Features

- J-Point depression with up-sloping ST segments.
- Tall, prominent, symmetric T waves in the precordial leads.
- Upsloping ST segment depression > 1mm at the J-point in the precordial leads.
- Absence of ST elevation in the precordial leads.
- ST segment elevation (0.5mm-1mm) in aVR.
- "Normal" STEMI morphology may precede or follow the DeWinter pattern.

Key Treatment Points

- Patient advocacy for a cardiology consult
- Monitor for potential emerging STEMI

12 Lead ECG Samples



[Further Reading](#)

References

1. DeWinter et al. A new ECG sign of proximal LAD occlusion. 2008. [\[Link\]](#)

